

Triumphs in Emergency and Critical Care

Celebrating Our Wins and Teams!



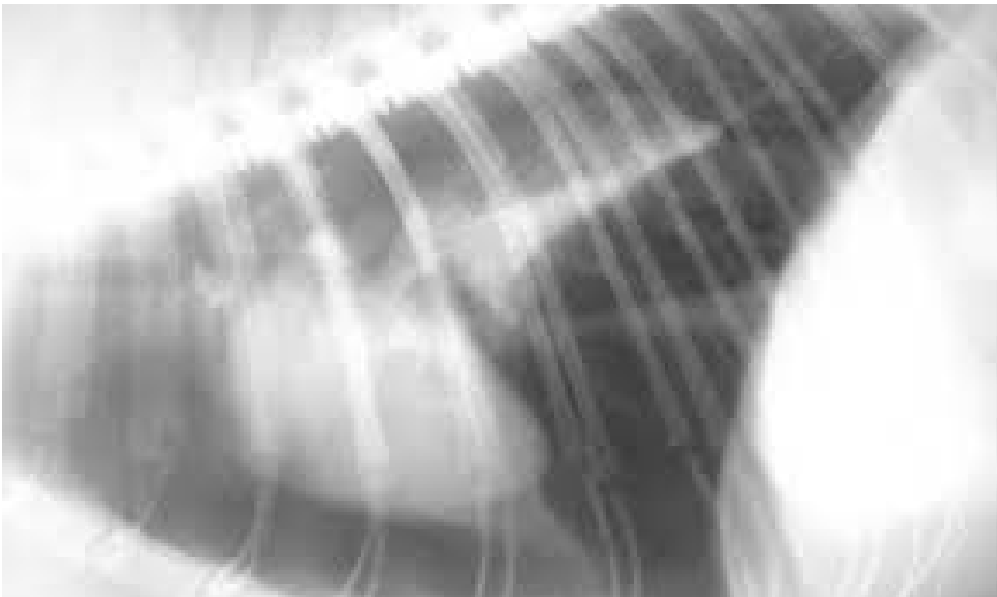
Jack

2-year old MN Beagle- HBC

Pneumothorax, pleural effusion, ventricular arrhythmias

Pleurodesis, chest tubes, continuous suction, transfusions

There were some very rough spots but he went home on Day 16!





Rosie- The Orange Girl!

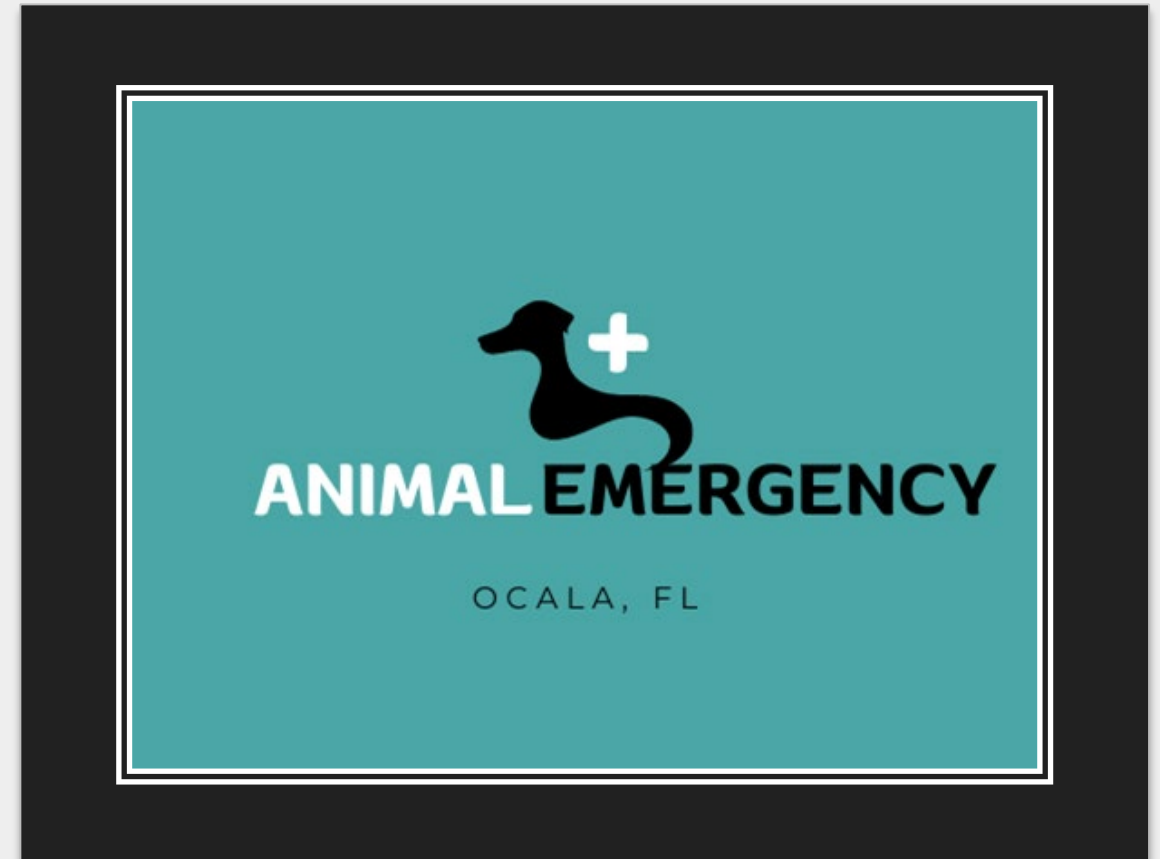2- year old female spayed DSH

Septic Peritonitis

Her ER doctor's first abdominal exploratory - nerve wracking for Rosie and her doc!

5 units of pRBC, 10 units of plasma

Started eating on day 6- discharged on day 7!



Meet Scout

10-year old MN Dachshund

Presented for acute collapse, weakness and a hemoabdomen

Diagnosed with anaphylaxis!!!!

Profound tachycardia, hypotension unresponsive to fluids and vasopressors

Clients came in to euthanize after 48 hours but decided to give him one more day

Discharged on Day 5 and doing amazing at home



ONTARIO
VETERINARY COLLEGE

Guidelines

-
- Important highlights of the case shared!
 - Photos of pets, diagnostic testing can be shared (please obtain client consent)
 - No client identifier on images, records or diagnostic test. Pet first name is OK!
 - Each case submitted should fit on one slide. Please include hospital name and location
 - Cases should be seen and managed by submitting hospital. Cases may have been managed at anytime in the past.
 - Hospitals may submit as many cases as they wish!